



## Mohs Micrographic Surgery for Melanoma in Situ

**Llana Pootrakul MD, PhD, FACMS**  
*Associate Professor, Mohs Micrographic Surgery and Dermatologic Oncology*  
*Department of Dermatology*  
*The Ohio State University Wexner Medical Center*

MedNet21  
Center for Continuing Medical Education

THE OHIO STATE UNIVERSITY  
WEXNER MEDICAL CENTER

## Objectives

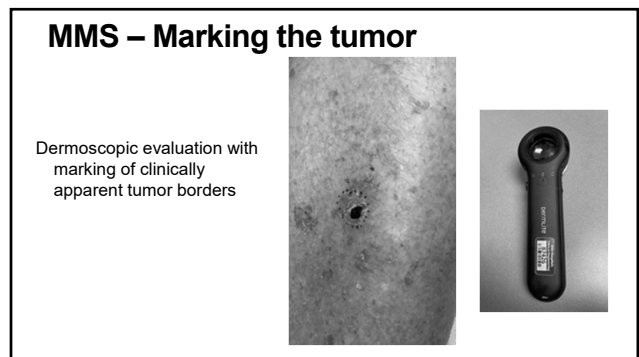
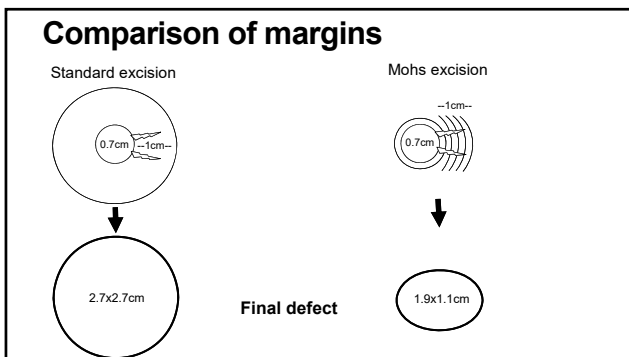
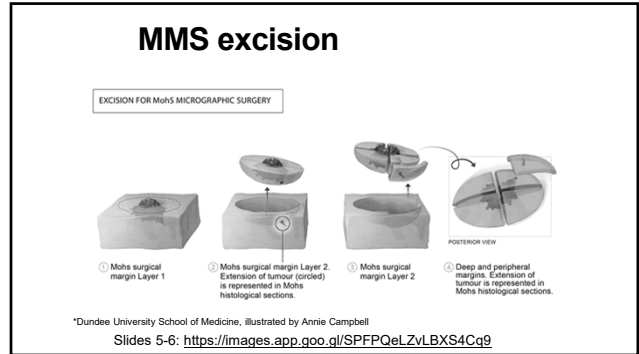
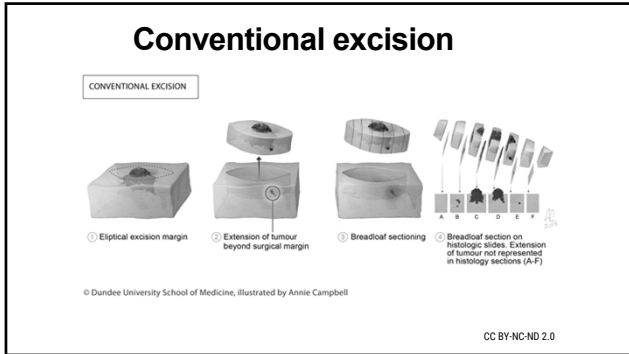
- Mohs micrographic surgery (MMS) – Overview
- NCCN guidelines for the management of melanoma in situ (MIS)
- Comprehensive histologic evaluation for melanoma in situ
  - Slow Mohs
  - MMS with MART-1
- Take home points

## Mohs Micrographic Surgery (MMS)

### Overview

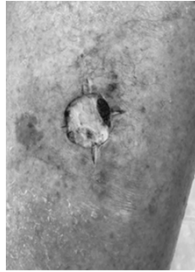## Key Features of MMS

- 100% microscopic tissue margin examination
- Highest evidence-based cure rate for skin cancers
- Precise excision and mapping of cancerous tissue
- Preservation of the maximum amount of non-cancerous tissue
- Mohs surgeon has total tissue control, true continuity of care
- Immediate re-excision of residual cancerous tissue as indicated; convenience
- Least complicated repair possible



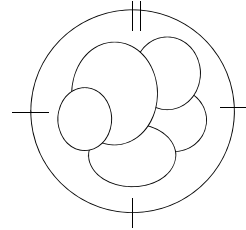
### MMS – Tumor extirpation

Hashmarks are created to maintain correct spatial orientation for precise mapping



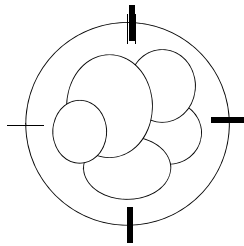
### Sample Mapping for MMS

- Sample mapping for MMS – full 360° section



### Sample Mapping for MMS


- Sample mapping for MMS – full 360° section



### MMS Tissue Processing



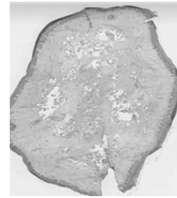
### En Face Frozen Processing of Fresh Tissue



Dr. Kathryn Shahwan

Mohs Surgery Tissue Processing Guidebook; permission to use images obtained from Mohs Surgeons Leading the Future primary author Dr. Kathryn Shahwan.

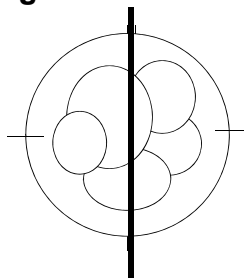
### Microscopic evaluation



Mohs Surgery Tissue Processing Guidebook; permission to use images obtained from Mohs Surgeons Leading the Future primary author Dr. Kathryn Shahwan

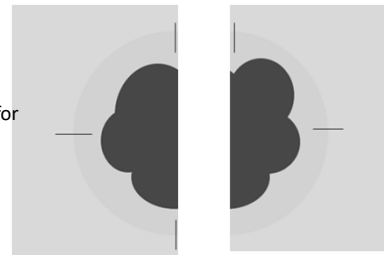
### Sample Mapping for MMS

- Sample mapping for MMS



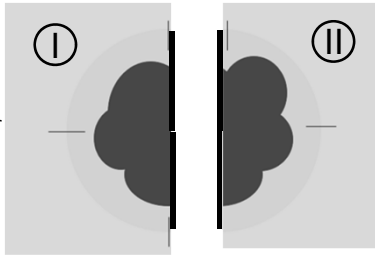
### Sample Mapping for MMS

- Sample mapping for MMS - bisected

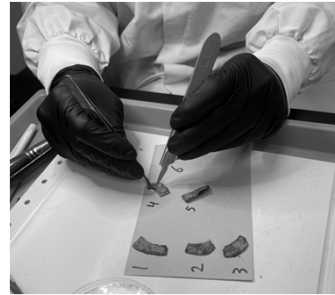


### Sample Mapping for MMS


- Sample mapping for MMS - bisected



### MMS Tissue Processing

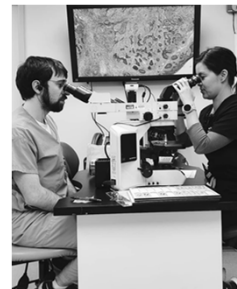

### MMS Tissue Processing

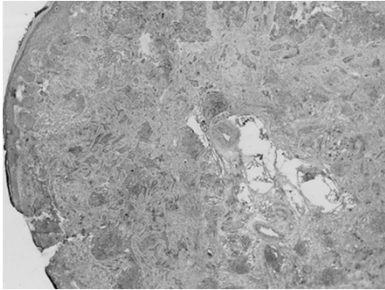


Mohs Surgery Tissue Processing Guidebook, permission to use images obtained from Mohs Surgeons Leading the Future primary author: Dr. Kathryn Stalwan

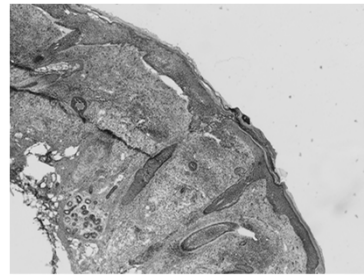
### MMS Slide Review



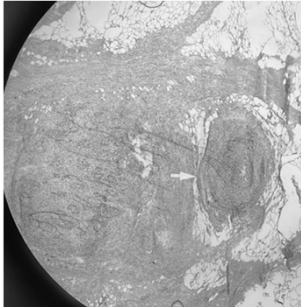
**MMS Histopathology – Basal cell carcinoma (BCC)**



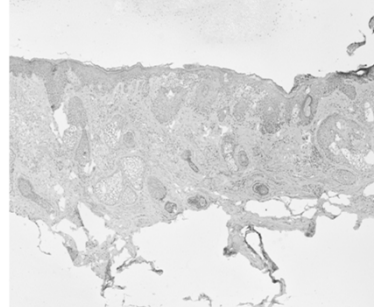
**MMS Histopathology – Basal cell carcinoma (BCC)**



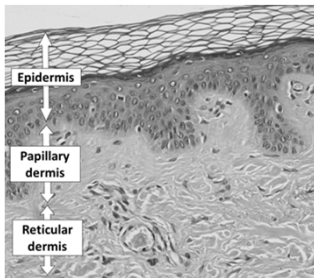
**MMS Histopathology – Squamous cell carcinoma (SCC)**



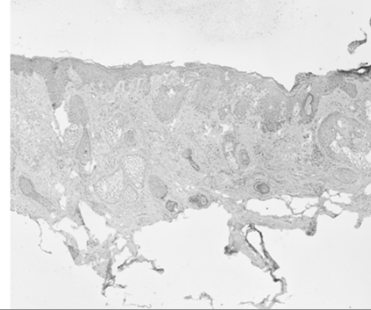
**MMS Histopathology – Melanoma in Situ (MIS)**



### Layers of the skin



### MMS Histopathology – Melanoma in Situ (MIS)



### NCCN Guidelines for Stage Tis Melanoma

- Routine imaging/labs not recommended
- Wide excision
  - Recommend peripheral surgical margins for melanoma in situ: 0.5-1.0cm
  - "Depth of excision into the subcutis may be adequate"
- "The gold standard for histologic assessment of excised melanoma is use of permanent sections. If complex reconstruction is anticipated, wound closure should generally be delayed until histologic margin assessment is complete."

NCCN Guidelines Version 2.2024 Melanoma: Cutaneous;  
NCCN.org/guidelines/nccn-guidelines

### NCCN Guidelines for Stage Tis Melanoma

- For large and/or poorly defined MIS and lentigo maligna, surgical margins >0.5cm may be necessary
- Techniques for comprehensive histologic evaluation of margins should be considered
  - Slow Mohs
  - MMS with MART-1
- If MMS is performed, use of frozen section melanocytic stains may assist in interpretation and has been associated with lower recurrence rates <sup>10</sup>Vieira et al, Etzkorn et al, Shin et al

NCCN Guidelines Version 2.2024 Melanoma: Cutaneous;  
NCCN.org/guidelines/nccn-guidelines

### Mohs Appropriate Use Criteria (Mohs AUC)

- Appropriate use criteria for Mohs micrographic surgery
  - JAAD 2012 report of the American Academy of Dermatology, American College of Mohs Surgery, American Society for Dermatologic Surgery Association, and the American Society for Mohs Surgery
- Paper attempts to define appropriateness of Mohs micrographic surgery dependent on tumor type, location, size, and patient characteristics
- Criteria Studied: 270 distinct scenarios in which MMS frequently considered or utilized <sup>\*Connolly et al</sup>

### Mohs AUC scoring system and categories defined as:

- 7-9: appropriate, acceptable
- 4-6: uncertain; may be appropriate and acceptable, however more research needed; clinical discretion imperative
- 1-3: inappropriate and not acceptable <sup>\*Connolly et al</sup>

### MMS for Melanoma in Situ/Lentigo Maligna

- MMS may be appropriate based on location
  - Sites M (Cheeks, forehead, scalp, neck, jawline, pretibial)
  - Sites H (Mask distribution of face, genitalia, hands, feet, ankles, nails)
- MMS may be appropriate based on tumor recurrence status <sup>\*Connolly et al</sup>

### Techniques for comprehensive histologic evaluation of margins

- Slow Mohs
- MMS with MART-1



### Slow Mohs

- Complete circumferential peripheral and deep margin assessment (CCPDMA)
- Specimens are sent for "stat" processing with formalin-fixed paraffin-embedded sections; approximately 24 hours.
- Slides are evaluated by a dermatopathologist the following day.
- Surgical appointments are scheduled every 2-3 days for next Slow Mohs stage vs reconstruction.
- Patients are advised that the entire process may take up to 2 weeks.

### Slow Mohs

- The complete circumferential peripheral and deep margin assessment (CCPDMA) is why we refer to "Slow Mohs" as Mohs.

### Key Features of MMS

- 100% microscopic tissue margin examination
- Highest evidence-based cure rate for skin cancers
- Precise excision and mapping of cancerous tissue
- Preservation of the maximum amount of non-cancerous tissue
- Mohs surgeon has total tissue control, true continuity of care
- Immediate re-excision of residual cancerous tissue as indicated; convenience
- Least complicated repair possible

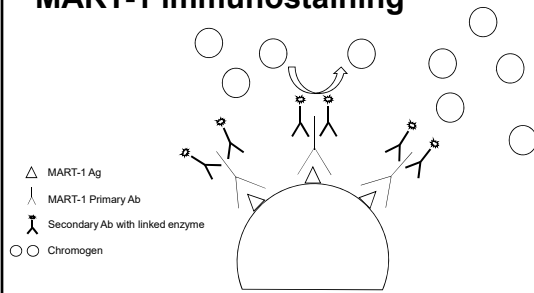
### Key Features of MMS (with MART-1)

- Outpatient procedure
- Local anesthetic
- Tumor is removed layer by layer
- Real-time updates every 45-60 minutes
  - MMS with MART-1 takes 2-3 hours for each result
- Definitive surgical treatment and reconstruction performed same day

### MART-1

- Melanoma antigen recognized by T cells (Melan-A, MART-1)
- 22 kDa cytoplasmic melanosome-associated glycoprotein
- Stains melanocytes; cells containing melanosomes
- Aids detection of melanoma and nevi
- Limited value in spindle and desmoplastic melanoma
- Risk of false-positive MIS with pigmented AKs

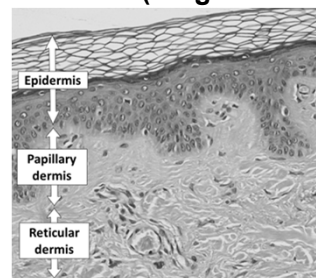
### MART-1 immunostaining



### MART-1 immunostaining controls

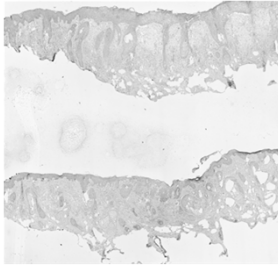
- Positive control – original biopsy
- Positive control (internal) – Tumor layer/debulk
  - Bread-loaf sections
- Negative control – Patient’s “normal” skin
- Standard frozen section control – H&E staining

### Melanoma in Situ (Stage Tis Melanoma)

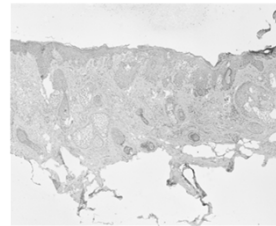


<https://images.app.goo.gl/MxikTkETuJmnp8Zv7>

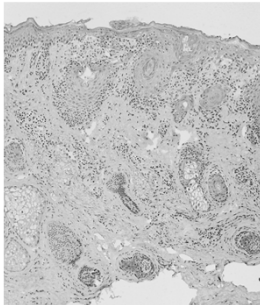
**Frozen Tumor Debulk Melanoma in Situ**



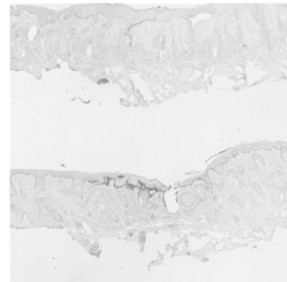
**Frozen Tumor Debulk Melanoma in Situ**



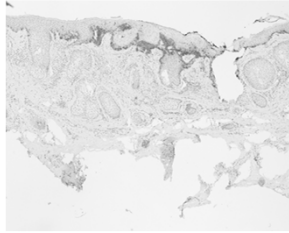
**Frozen Tumor Debulk Melanoma in Situ**



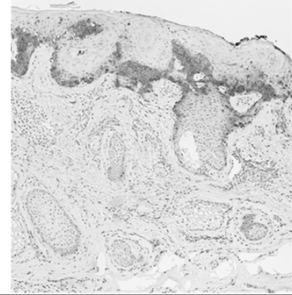
**MART-1 Staining**



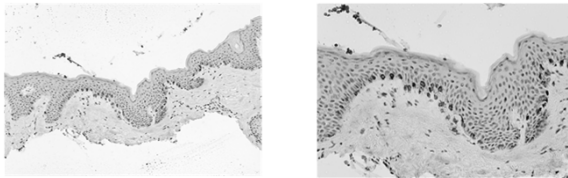
**MART-1 Staining**



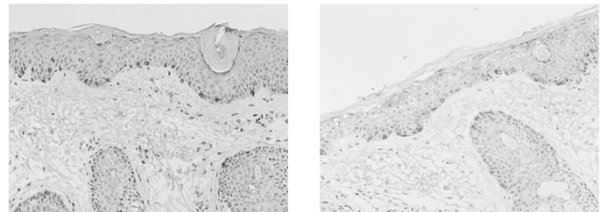
**MART-1 Staining**

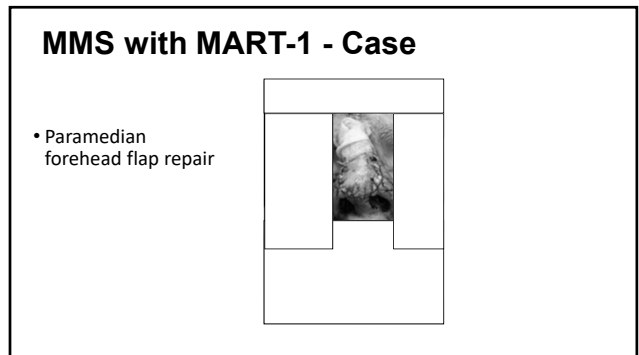
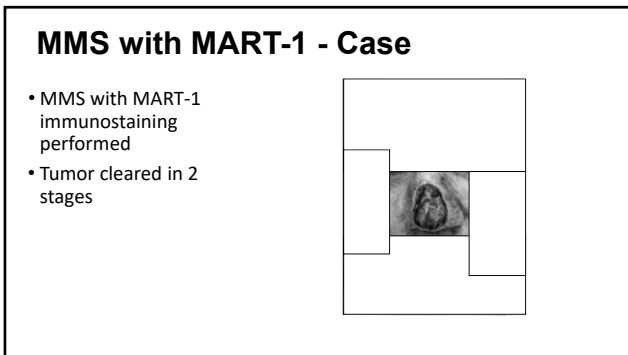
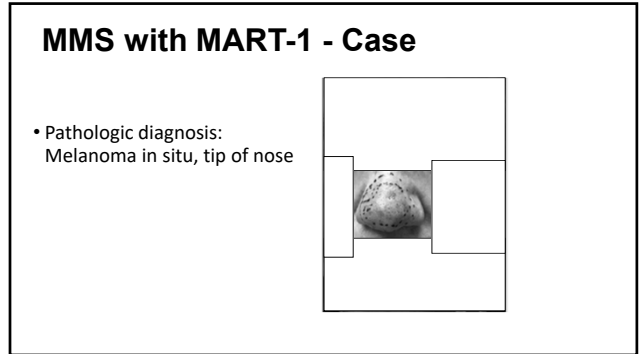
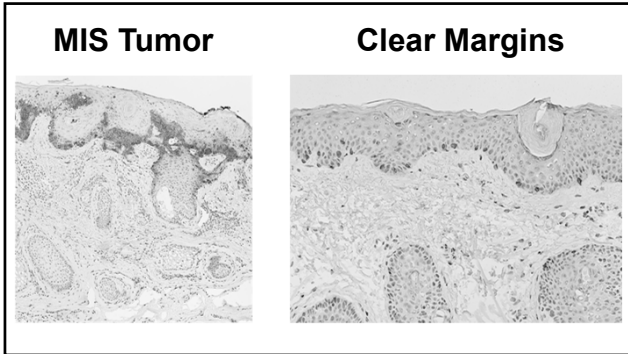


**Negative control MART-1**



**Clear margins MIS**





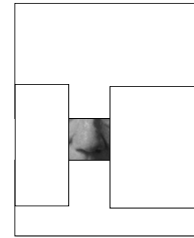
### MMS with MART-1 - Case

- Paramedian forehead flap repair

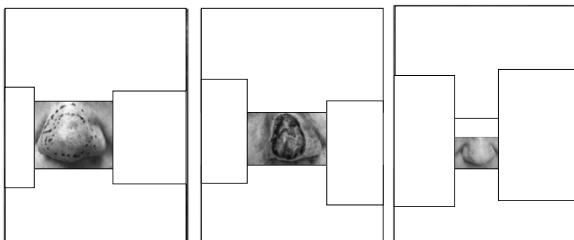


### MMS with MART-1 - Case

- Patient update photo 6 weeks following MMS with reconstructive surgery

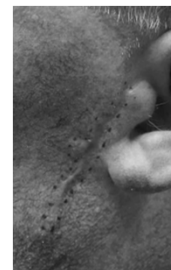


### MMS with MART-1 - Case



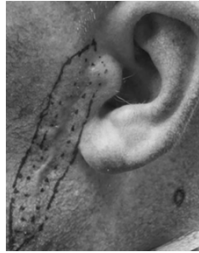### MMS with MART-1 - Case

- Patient s/p wide excision for invasive MM
- Pathology shows residual MIS



### MMS with MART-1 - Case

- Initial margins and negative control marked



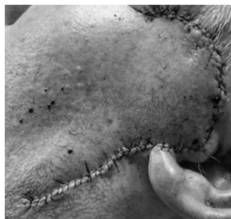### MMS with MART-1 - Case

- Final defect
- 2 stages of MMS with MART-1



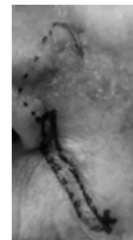
### MMS with MART-1 - Case

- Reconstruction with rotation flap



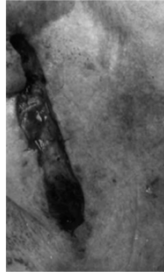
### MMS with MART-1 - Case

- Patient s/p wide excision for invasive MM
- Pathology shows residual MIS



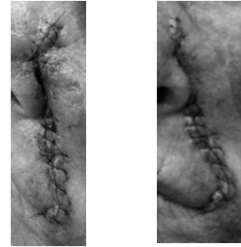
### MMS with MART-1 - Case

- Final defect
- 2 stages of MMS with MART-1



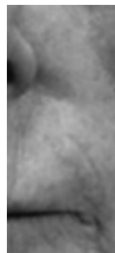
### MMS with MART-1 - Case

- Repair with crescentic advancement flap and secondary intention



### MMS with MART-1 - Case

- 2 month post operative photo



### MART-1 cases performed at The James MMT4

- Primary tumors – 79%
- Residual/recurrent tumors – 21%
- Internal referrals - 37%
  - Derm - 50%
  - Non-derm specialties – 50%
- External referrals - 63%
- Other Mohs surgeon - 14%



## Take home points

- The primary goal of MMS is 100% margin evaluation for complete tumor removal
- MMS demonstrates the highest cure rates for non-melanoma skin cancers and is shown to be effective with lower recurrence rates than standard excision for MIS
- Precise mapping of MMS allows maximum preservation of normal skin
- MART-1 immunostaining optimizes the identification of MIS in frozen sections
- MMS with MART-1 offers patients the option of same day treatment for MIS for tumors in high risk sites

## References

- Connolly SM et al. AAD/ACMS/ASDSA/ASMS 2012 Appropriate Use Criteria for Mohs Micrographic Surgery: A Report of the American Academy of Dermatology, American College of Mohs Surgery, American Society for Dermatologic Surgery Association, and the American Society for Mohs Surgery. *Dermatologic Surgery* 38(10):p 1582-1603, October 2012.
- Vieira C et al. Recurrence Rate for Melanoma Excised by Mohs Micrographic Surgery Without Immunostaining. *Dermatol Surg*. 2022 May;148(5):492-497.
- Etzkorn et al. Low recurrence rates for in situ and invasive melanomas using Mohs micrographic surgery with melanoma antigen recognized by T cells 1 (MART-1) immunostaining: tissue processing methodology to optimize pathologic staging and margin assessment. *J Am Acad Dermatol*. 2015 May;72(5):840-50.
- Shin et al. Mohs micrographic surgery with MART-1 immunostaining has durable low local recurrence rates for in situ and invasive melanomas. *J Am Acad Dermatol* 2021 Jan;84(1):196-198